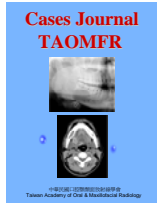


## Intraosseous Neurilemmoma (Schwannoma) of the Mandible - Report of a Case

Mu-Yen Hsieh<sup>1</sup>, Chun-Ming Chen<sup>2</sup>, Li-Min Lin<sup>1,\*</sup>, Yuk-Kwan Chen<sup>1,\*</sup>

Departments of <sup>1</sup>Oral Pathology, <sup>2</sup>Oral & Maxillofacial Surgery, School of Dentistry, College of Dental Medicine, Kaohsiung Medical University, Kaohsiung Medical University Hospital, Kaohsiung, Taiwan



**Cases Journal TAOMFR 2009; 1: 2**

\* Corresponding author. Address: Department of Oral Pathology, Faculty of Dentistry, College of Dental Medicine, Kaohsiung Medical University, 100, Shih-Chuan 1st Road, Kaohsiung, Taiwan.

Tel.: +886 7 3121107~7007; fax: +886 7 3210637. E-mails: yukkwa@kmu.edu.tw (Y.-K. Chen),

limin@cc.kmu.edu.tw (L.-M. Lin)

Keywords: central neurilemmoma, schwannoma, mandible

Received: 2 December 2009; Accepted: 25 December, 2009

**N**eurilemmoma is a benign neoplasm derived from Schwann cells, which cover myelinated peripheral nerves. This lesion was first described by Verocay in 1910 as "neurinoma" [1]. The term of 'neurilemmoma' was initiated by Stout in 1935 [2]. To date, the etiology of this disease is still uncertain. It is frequently located in the soft tissue of the head and neck areas with a particularly predilection to grow in the tongue [3,4]. Neurilemmoma occurring in the soft tissue is more common than its intraosseous counterpart. Central neurilemmoma represents less than one percent of the bony neoplasms [5]. This report presents an uncommon case of intraosseous neurilemmoma occurring in the mandible.

### CASE PRESENTATION

A 54-year-old Taiwan male patient visited his family dentist with a chief complaint of mobility of the lower right first molar for a few months duration. After periapical radiographic examination, his family dentist noted a shadow of radiolucency over the apical areas of the three right molar teeth. The patient was then referred to the Department of Oral and Maxillofacial Surgery of our institution by his local family dentist for further examination. The patient did not chew betel-quid and smoked cigarette but drank alcohol casually. He had a medical history of

hypertension and under medication control.

Intraoral examination revealed no evident of swelling over the mandibular right buccal vestibule. The surface mucosa of the right buccal vestibule over the right lower molar teeth appeared smooth and normal. No pain, discharge or paraesthesia was complained but grade II mobility of the second molar was evident. Vitality test was positive for tooth 46, 47 and 48 respectively. Aspiration of the lesion yielded negative finding.

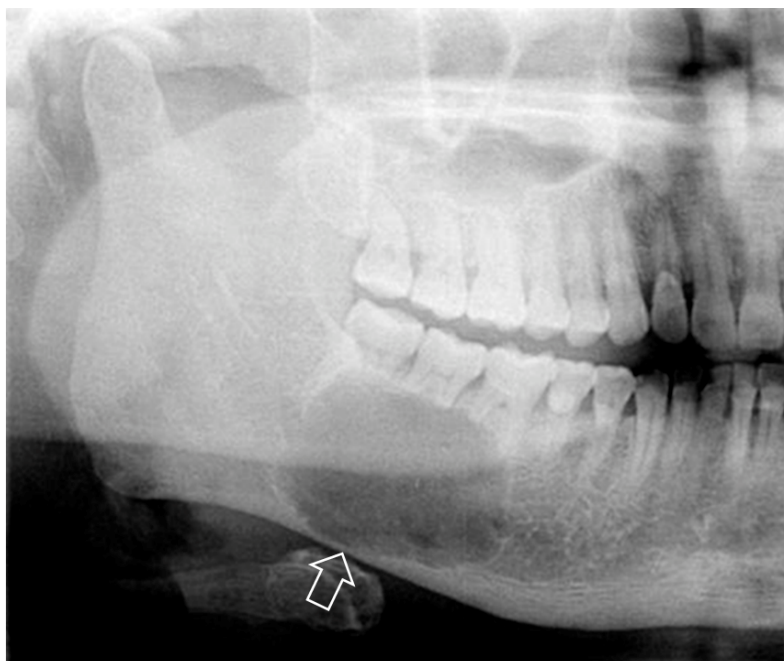
On panoramic radiographic

examination, there was a well-defined, unilocular, oval-shaped, radiolucent image with corticated rim under the apical areas of tooth 46, 47, 48 extending from the mesial aspect of tooth 46 to the distal aspect of 48, and from half of the root of tooth 46 to about 2 mm above the inferior border of mandible body, measured about  $4 \times 2.5$  cm<sup>2</sup> in diameter. No tooth displacement but external root resorption of tooth 46, 47 and 48 were evident. Right inferior alveolar canal was involved by the lesion. Moreover, right lower cortical bone thinning without bony expansion was noted (Figure 1). On the other hand, computerized tomography (CT) revealed a well-defined soft tissue lesion over the right mandibular body with lingual cortical plate perforation (Figure 2). Then, the patient was arranged for surgical excision under the clinical impression of intraosseous benign tumor.

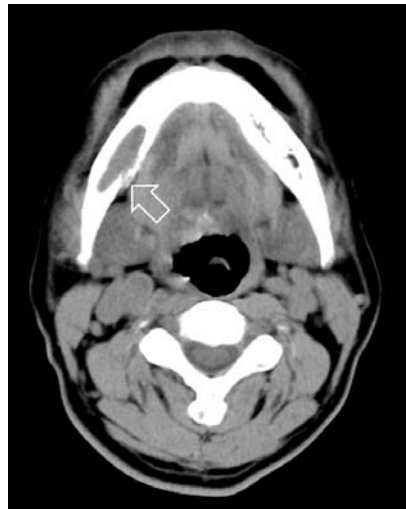Upon general anesthesia, the lesion was completely surgically removed. The

specimen was sent for pathological examination. Grossly, the tissue specimen was measured approximately 4×2 cm in diameter, and on cut section, it revealed a solid whitish tumor.

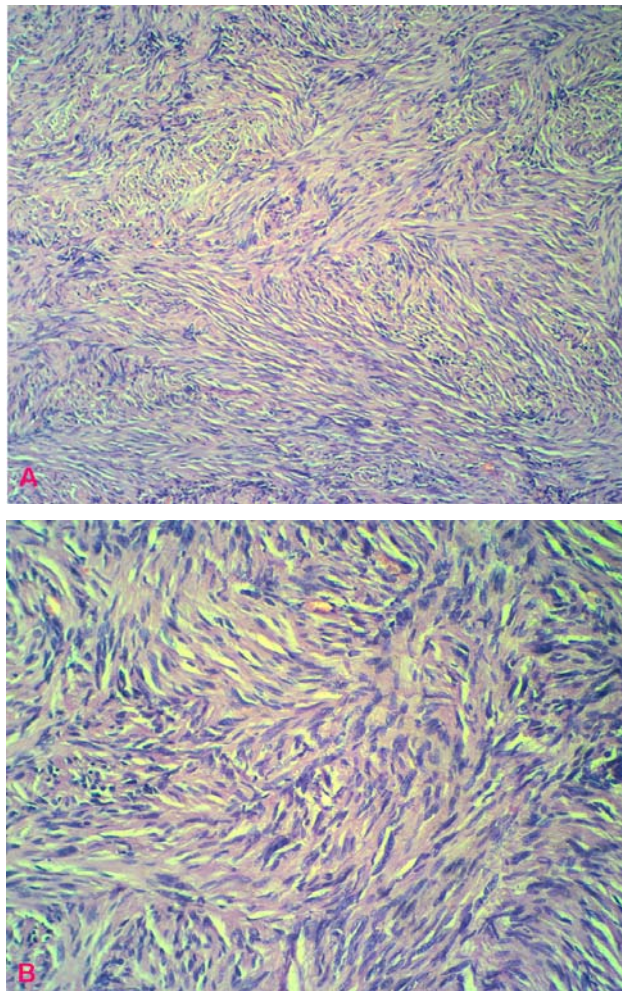
On pathological examination, the surgical specimen consisted of bundles of spindle cells in Antoni A and Antoni B areas arranged in a palisading pattern, interspersed with small hyaline acellular structures, the Verocay bodies (Figure 3A &B). The histopathological diagnosis was that of an intraosseous neurilemmoma over the right mandibular body area. Immunohistochemistry was done with an S-100 marker, which revealed diffuse positivity in the tumor cells (Figure 4), and negative with desmin, vimentin and smooth muscle actin (SMA), which further confirmed the diagnosis of neurilemmoma. The patient tolerated the procedure well. No recurrence has been noted after regular follow-up for three years.



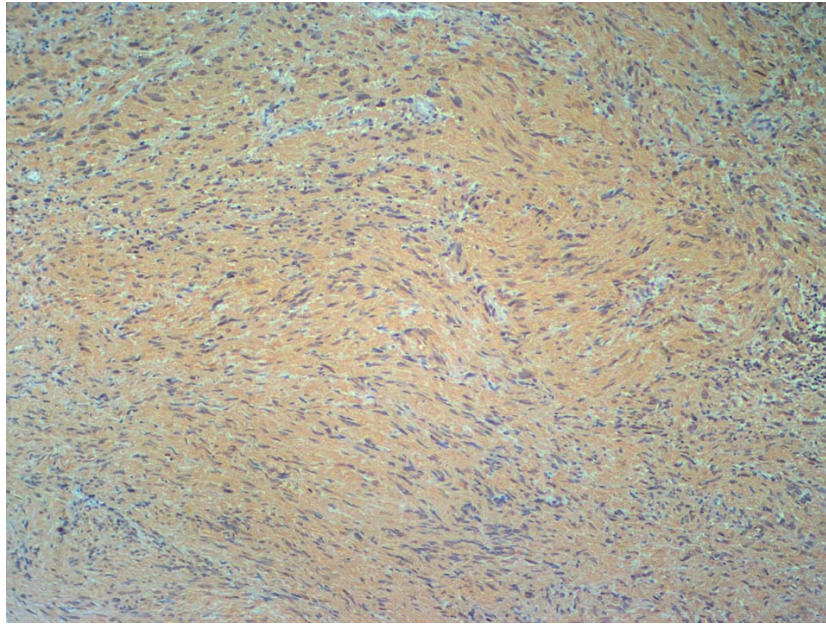
**Figure 1** The cropped panoramic radiography revealed a well-defined, unilocular, oval-shaped, radiolucent shadow with corticated rim extending from the mesial aspect of tooth 46 to the distal aspect of 48. External root resorptions of tooth 46, 47 and 48 as well as cortical thinning (arrow) were evident



**Figure 2** The axial view of computerized tomography revealed a well-defined soft tissue lesion over the right mandibular body area. The lingual cortical plate was perforated (arrow)



**Figure 3** Histological examination revealed a lesion consisting of bundles of spindle cells in Antoni A and Antoni B areas arranged in a palisading pattern, interspersed with the Verocay bodies (Hematoxylin-eosin stain, A  $\times 100$ ; B  $\times 200$ )



**Figure 4** Immunohistochemical staining of S-100 revealed diffuse positivity in the tumor cells (Avidin-biotin peroxidase complex staining  $\times 100$ )

**COMMENTS**

Intraosseous neurilemmomas of the jaws are rare. In a literature presented by Chi et al [5], there have been 44 reported cases of neurilemmomas occurred in the jaws accounting for less than one percent of benign primary bone tumors. Among these 44 cases, the most common site of occurrence is the mandible (n=39) with only five cases occurred in the maxilla [5]. The predominant mandibular occurrence compared to the maxilla may be due to the lengthy intraosseous pathway of the inferior alveolar nerve within the lower jaw [6]. Moreover, intraosseous mandibular neurilemmomas are frequently located in the posterior body and the ascending ramus and the symphysis region can also be involved [5]. The current case is also localized to the posterior mandibular body extending from the right first to third molars. On rare occasions, intraosseous mandibular neurilemmomas occurred at the periapical area mimicked apical pathoses [7-9]. Interestingly, a mandibular neurilemmoma occurred at

the periapical area was concurrent with an adjacent radicular cyst leading to a bilocular radiographic appearance has been reported [9]. The average age of occurrence of intraosseous neurilemmomas of the jaw has found to be 34 years ranging from 8-72 years and there is a distinct female predilection [5]. For the present case, the patient was a male aged 54 years.

Neurilemmomas are slow growing benign tumors. The predominant clinical presentation is bony swelling, followed by pain and paraesthesia [10]. Pain may happen when the lesion encroaches upon the nearby nerves and paraesthesia may derive with lesion originating from the inferior alveolar canal [11]. However, for the present case, neither mandibular swelling nor paresthesia was noted clinically. This could explain why the patient did not aware the growth of this lesion until it has been alerted by his family dentist after noting a lesion of radiolucence after taking periapical radiography.

Radiographically, neurilemmomas of

the jaw are well-defined, unilocular radiolucencies with a thin sclerotic border. Therefore, the differential diagnosis, both clinically and radiographically, should include odontogenic cysts and tumors (keratocystic odontogenic tumor, ameloblastoma, Pindborg tumor), and nonodontogenic tumors such as central hemangioma, and central giant cell granuloma [10]. For the present case, the possibility of cystic lesions has been ruled out because of the negative aspiration finding. Moreover, it should be noted that additional radiologic characteristics such as external root resorption, cortical thinning, spotty calcification, cortical expansion, and peripheral scalloping may also be manifested [5]. Hence, in order to have a complete radiological feature of the lesion, besides conventional oral radiographic imagings, additional imaging modalities such as CT, and magnetic resonance imaging have also been suggested [10]. In this case, conventional panoramic radiography revealed a well-defined, unilocular radiolucence with corticated rim causing external root resorption and lower cortical bone thinning. However, additional radiologic feature of lingual plate perforation of the lesion has been detected on CT imaging.

Microscopically, neurilemmomas are classically characterized by encapsulation but unencapsulated lesions have also been reported [5]. For the present case, no capsule can be identified histologically. The tumor is characterized with variable proportion of so-called Antoni A (spindle cells with their nuclei arranged in rows and displaying a palisading effect, and with Verocay bodies which represent acellular zones) and Antoni type B (less cellular and less organized non-organic areas) zones [12,13]. Stained only with haematoxylin and eosin, a misdiagnosis

of leiomyoma is possible because leiomyoma may also show palisading spindle cells arranging in rows (Antoni type tissue) as in neurilemmoma. Therefore, it is also essential to include an immunohistochemical staining of S-100 for suspected tumors of neural origin because S-100 protein is positive in all neural tumors [11]. In this case, immunohistochemical staining with desmin, vimentin and SMA, which are specific for leiomyoma, were negative and immunohistochemical findings for S-100 protein revealed intense positivity for S-100. Therefore, a tumor of neural origin is confirmed for our patient. Moreover, neurilemmomas exhibit both a benign and a malignant form. Malignant transformation of a benign lesion as well as primary malignant neurilemmoma have also been reported [14,15]; therefore, thorough histological examination and regular follow-up is essential.

The recommended treatment modality for intraosseous neurilemmomas is surgical resection, together with regular follow-up while the implicated nerve can be resected to avoid the likelihood of recurrence [5]. Incomplete resection of the lesion may lead to recurrence, and hence a periodic follow-up is necessary [5]. For the present case, surgical excision was the treatment of choice and no recurrence has been noted after follow-up for three years.

### CONCLUSIONS

Both clinical and radiographic features of the present case are closely mimic benign odontogenic tumors, which can easily be confusing to the dentists. Although it is rare, we suggest that a complete differential diagnosis for such a lesion should always include a tumor of neural origin. □

### THE AUTHORS



**Dr. Mu-Yen Hsieh** is first-year resident in Department of Oral Pathology, Kaohsiung Medical University, Kaohsiung, Taiwan



**Dr. Chun-Ming Chen** is associate professor of Department of Oral & Maxillofacial Surgery, Kaohsiung Medical University, Kaohsiung, Taiwan



**Dr. Li-Min Lin** is professor of Department of Oral Pathology, Kaohsiung Medical University, Kaohsiung, Taiwan



**Dr. Yuk-Kwan Chen** is assistant professor & head of Department of Oral Pathology, Kaohsiung Medical University, Kaohsiung, Taiwan

This article has been peer reviewed

**REFERENCES**

- Verocay J. Zur Kenntnis der Neurofibrome. *Beitr Path Anat* 1910;**48**:1-68.
- Baranovic M, Macan D, Begovic EA, Luksic I, Brajdic D, Manojlovic S. Schwannoma with Secondary erosion of mandible: Case report with review of literature. *Dentomaxillofac Radiol* 2006;**35**:456-60.
- Artzi Z, Taicher S, Nass D. Neurilemmoma of the mental nerve. *J Oral Maxillofac Surg* 1991;**49**:196-200.
- Enzinger FM, Weiss SW. Benign tumors of peripheral nerves. In: *Soft tissue tumors* (4th ed). St. Louis, MO: Mosby Year Book, Inc., 2001, p. 1111-200.
- Chi CA, Carey J, Muller S. Intraosseous Schwannoma of the mandible: A case report and review of literature. *Oral Surg Oral Med Oral Pathol Oral Radiol Endod* 2003;**96**:54-65.
- Gordon EJ. Solitary intraosseous neurilemmoma of the tibia: review of intraosseous neurilemmoma and neurofibromas. *Clin Orthop* 1976;**117**:271-81.
- Buric N, Jovanovic G, Pesic Z, Krasic D, Radovanovic Z, Mihailovic D, Tijanac M. Mandible schwannoma (neurilemmoma) presenting as periapical lesion. *Dentomaxillofac Radiol* 2009;**38**:178-81.
- Martins MD, Taghloubi SA, Bussadori SK, Fernandes KPS, Paolo RM, Martins MAT. Intraosseous schwannoma mimicking a periapical lesion on the adjacent tooth: case report. *Int Endodon J* 2007;**40**:72-8.
- Pimkhaokham A, Piriyaupong P, Swasdison S, Pimkhaokham S, Tung P. Central neurilemmoma of the jaw in concurrence with radicular cyst: a case report. *Oral Surg Oral Med Oral Pathol Oral Radiol Endod* 2006;**102**:e34-e36.
- Sadeghi ME, Koenig JL, Clarck D. Intrabony neurilemmoma: Diagnosis and management. *J Am Dent Assoc* 1998;**129**:729-32.
- Chrysomali E, Papanicolaou SI, Dekker NP, Regezi JA. Benign neural tumors of the oral cavity. *Oral Surg Oral Med Oral Pathol Oral Radiol Endod* 1997;**84**:381-90.
- Lacerda AS, Brentegani LG, Rosa AL, Vespucio MVO, Salata LA. Intraosseous Schwannoma of Mandibular Symphysis: Case report. *Braz Dent J* 2006;**17**:255-8.
- Shafer, Hine and Levy. A text book of Oral pathology 4th ed. India: Saunders; 2002. p. 208.
- Murphy J, Guinta JL. Atypical central neurilemmoma of the mandible. *Oral Surg Oral Med Oral Pathol* 1984;**59**:275-8.
- Ohnishi M, Tanaka Y, Tutui T, Bann S. Extensive malignant schwannoma of the mandibular nerve case report. *Int J Oral Maxillofac Surg* 1992;**21**:280-1.